

SEGMENTATION OF PROSTATE IN MRI IMAGES
USING GRAPH-CUT SEGMENTATION

NURUL AZLAN BIN ISTAB

ELECTRICAL AND ELECTRONIC ENGINEERING
UNIVERSITI TEKNOLOGI PETRONAS
JANUARY 2016

NURUL AZLAN BIN ISTAB

B. ENG. (HONS) ELECTRICAL AND ELECTRONIC ENGINEERING

JANUARY 2016

**SEGMENTATION OF PROSTATE IN MRI IMAGES
USING GRAPH-CUT SEGMENTATION**

by

Nurul Azlan Bin Istab

16577

Dissertation submitted in partial fulfilment of
the requirement for the
Bachelor of Engineering (Hons)
Electrical and Electronic Engineering

JANUARY 2016

Universiti Teknologi PETRONAS
Bandar Seri Iskandar
32610 Tronoh
Perak Darul Ridzuan

CERTIFICATION OF APPROVAL

SEGMENTATION OF PROSTATE IN MRI IMAGES USING GRAPH-CUT SEGMENTATION

by

Nurul Azlan Bin Istab
16577

A project dissertation submitted to the
Electrical and Electronic Engineering Programme
Universiti Teknologi PETRONAS
In partial fulfilment of the requirement for the
BACHELOR OF ENGINEERING (Hons)
ELECTRICAL AND ELECTRONIC ENGINEERING

Approved by,

Dr. Nidal Kamel

UNIVERSITI TEKNOLOGI PETRONAS
TRONOH, PERAK

January 2016

CERTIFICATION OF ORIGINALITY

This is to certify that I am responsible for the work submitted in this project, that the original work is my own except as specified in the references and acknowledgments and that the work contained herein have not been undertaken or done by unspecified sources or persons.

Nurul Azlan Bin Istab

ABSTRACT

Prostate cancer has become one of the highest cancer-related death cases over the last few years in the West. This cancer affects only men. Statistics has shown that there is a big rise in the number of estimation cases over the last years. The increase in the number of these cases leads to accurate diagnoses at early stages enabling early intervention. Numbers of clinical practices are also introduced. One of these practices is the use of the Magnetic Resonance Imaging (MRI) scanner. However, images produced show a poor contrast of soft tissue between the surrounding tissue and prostate gland. This article aims to use the Graph-cut as the method segmentation of images.

Index Terms – Prostate Gland, MRI scanner, MATLAB

ACKNOWLEDGEMENT

First of all, I would like to express my gratitude to Dr. Norashikin binti Yahya and Dr. Nidal Kamel who are not only my supervisor but also a mentor who assisted and guided me throughout my Final Year Project. They have shared their valuable experience and knowledge during the whole period of Final Year Project. Without their guidance and advices, I would not be able to complete this course.

Also, I would like to thank my family and friends, who always give me a support throughout the completion of this course.

TABLE OF CONTENTS

ABSTRACT.....	iv
ACKNOWLEDGEMENT	v
TABLE OF CONTENTS.....	vi
LIST OF FIGURES	viii
LIST OF TABLES.....	x
CHAPTER 1	1
1.1 Background of Study.....	1
1.2 Problem Statement	2
1.3 Objective and Scope of Study	3
CHAPTER 2	4
2.1 Prostate Cancer	4
2.2 Clinical Practices.....	4
2.2.1 Magnetic Resonance Imaging (MRI).....	5
2.3 Method of Segmentation	5
2.3.1 Contour and Shape Based Method.....	5
2.3.2 Deformable Model Segmentation	6
2.3.3 Region Based Method.....	8
2.3.4 Supervised and Unsupervised Classification Method.....	8
2.3.5 Graph Based Segmentation.....	9
2.3.6 Hybrid method	10
CHAPTER 3	11
3.1 Research Methodology.....	11
3.1.1 Literature Review	11
3.1.2 Selection of Prostate Segmentation Method	12
3.1.3 Basic Block Diagram of Design	12
3.1.4 Method Testing	13
3.2 Project Activities.....	13
3.3 Key Milestones	14
3.3.1 Literature Review	14
3.3.2 Selection of Method.....	14
3.3.3 Testing the Method on MATLAB	14

3.3.4 Documentation and Reporting	15
3.4 Gantt Chart.....	15
3.5 Tools and Equipment Required.....	15
CHAPTER 4:	16
4.1 Discussion	16
4.1.1 Prostate Gland.....	16
4.1.2 Prostate Cancer	17
4.1.3 The Location of Prostate Cancer.....	18
4.1.4 The Diagnoses and Staging of the Prostate Cancer	19
4.2 Result	21
4.2.1 Segmentation Using Edge Based	24
4.2.2 Segmentation Using Mean Shift	25
4.2.3 Segmentation Using Graph-cut.....	31
4.2.4 The comparison between Graph-cut segmentation and Mean Shift segmentation	35
4.2.5 The Accuracy of Segmentation of Graph-cut	37
CHAPTER 5:	39
5.1 Conclusion	39
5.2 Recommendation and Future Work	39
REFERENCES	40
APPENDIX.....	44

LIST OF FIGURES

Figure 1: Block Diagram of the Process of Segmentation	12
Figure 2: Flow chart of project activities	13
Figure 3: Anatomy of Male Reproduction.....	17
Figure 4: Structure of Prostate	18
Figure 5: Stage of prostate cancer.....	21
Figure 6: Image (a).....	23
Figure 7: Image (b)	23
Figure 8: Image (c).....	23
Figure 9: Image (d)	23
Figure 10: Image (e).....	23
Figure 11: Image (f)	23
Figure 12: Image (g)	23
Figure 13: Image (h)	23
Figure 14: Image (i)	23
Figure 15: Original MRI image	24
Figure 16: Original Image Goes Through Prewitt Filter.....	24
Figure 17: Filtered Image with Clean Edge Of The R.O.I.....	25
Figure 18: Image (b)	26
Figure 19: Adjusted Image (b).....	26
Figure 20: X=40, y=1.....	27
Figure 21: X=40, y=2.....	27
Figure 22: X=40, y=3.....	27
Figure 23: X=40, y=4.....	27
Figure 24: X=40, y=5.....	27
Figure 25: X=40, y=6.....	27
Figure 26: X=40, y=7.....	27
Figure 27: X=40, y=8.....	27
Figure 28: X=40, y=9.....	27
Figure 29: X=40, y=10.....	27
Figure 30: Mean Shift Figure (a)	29
Figure 31: Mean Shift Figure (b)	29
Figure 32: Mean Shift Figure (c)	29
Figure 33: Mean Shift Figure (d)	29
Figure 34: Mean Shift Figure (e)	29
Figure 35: Mean Shift Figure (f).....	29
Figure 36: Mean Shift Figure (g)	29
Figure 37: Mean Shift Figure (h)	29
Figure 38: Mean Shift Figure (i).....	29
Figure 39: Image (d)	30
Figure 40: Figure(d) after adjusted contrast.....	30
Figure 41: Mean Shift Figure (d)	30

Figure 42: Image (a).....	31
Figure 43: Figure (a) after adjusted contrast.....	31
Figure 44: Mean Shift Figure (a)	31
Figure 45: Image (a) K=1	32
Figure 46: Image (a) K=2	32
Figure 47: Image (a) K=3	32
Figure 48: Image (a) K=4	32
Figure 49: Image (a) K=5	32
Figure 50: Image (a) K=6	32
Figure 51: Image (a) K=7	32
Figure 52: Image (a) K=8	32
Figure 53: Image (a) K=9	32
Figure 54: Image (a) K=10	32
Figure 55: Image (a) pre K-mean.....	32
Figure 56: k=4 Figure (a).....	33
Figure 57: k=4 Figure (b).....	33
Figure 58: k=4 Figure (c).....	33
Figure 59: k=4 Figure (d).....	33
Figure 60: k=4 Figure (e).....	33
Figure 61: k=4 Figure (f)	33
Figure 62: k=4 Figure (g).....	33
Figure 63: k=4 Figure (h).....	33
Figure 64: k=4 Figure (i).....	33
Figure 65: Image (i)	34
Figure 66: Figure (i) after adjusted contrast.....	34
Figure 67: k=4 Figure (i).....	34
Figure 68: Image (e).....	35
Figure 69: Figure(e) after adjusted contrast.....	35
Figure 70: k=4 Figure (e).....	35
Figure 71: MRI images with selected parts.	37
Figure 72: selected image compiled in vertical row	38
Figure 73: Selected Image Compiled In Vertical Row	38
Figure 74: Result Of Simulation	38
Figure 75: Gantt chart	44

LIST OF TABLES

Table 1: Type of Tumor.....	19
Table 2: Staging of Cancer.....	20
Table 3: Selected MRI Images.....	23
Table 4: Result of Adjusted Brightness.....	26
Table 6: Image (b) with different y-axis.....	27
Table 7: Result of Mean Shift on All Images.....	29
Table 8: Result Image (d).....	30
Table 9: Result of Image (a).....	31
Table 10: Image (a) with vary number of cluster (k).....	32
Table 11: All images with k-mean of k=4.....	33
Table 12: Result of image (i).....	34
Table 13: result of image (e).....	35
Table 14: The Comparison between Mean-Shift Segmentation and Graph-Cut Segmentation.	36
Table 15: Result of Simulated Images.....	38

CHAPTER 1

INTRODUCTION

1.1 Background of Study

Prostate cancer is a plague disease to men. This type of cancer typically affects only males. It's reported that a huge number of patients comes from the United States of America (USA), New Zealand and Australia, a stark contrast to the situation in Central and South Asia which recorded the lower number of cases of prostate cancer are recorded [1].

This cancer is growing silently in male prostate without registering any symptoms to the patient at early stage. However, the patient will later experience a problem with urination and erectile dysfunction. According to research, prostate cancer normally occurs in patients of the age range 65 years old and above. It's really a rare case if the patient is under 40 years old [2].

Prostate cancer is one of cancer that has caused the highest rate of the death cases around the globe especially in the western country such as the United States of America. The number of new patients is estimated to rise to 233,000 men and number of death will be 29,480 [3].

However, prostate cancer is curable and treatable in its early stages by doing the clinical practice for early diagnosis. The enhancement of the imaging of the diagnosis is carried out to ensure the result is clear enough to do the analysis. The diagnosis is carried out using segmentation method.

1.2 Problem Statement

Currently, a lot of clinical practices have been introduced to the medical world on the segmentation of images. Diagnoses are commonly derived from clinical practices such as Magnetic Resonance Imaging (MRI) as well as Trans Rectal Ultrasound (TRUS). CT scan or Computed Tomography (CT) imaging is also a known common clinical practice for diagnoses of the prostate gland. For this research, the spotlight will be on the MRI scanner.

In addition to the above, the body composition of a patient varies from one to the other. Variability of the soft tissue, shape, size and texture information make the task of segmentation on all clinical practices complicated. Throughout this experiment, the aim is to find the efficient method for segmentation of prostate that applies the application of MATLAB in which the method suggested is using the graph-cut method.

1.3 Objective and Scope of Study

The objectives of this study are:

- a) To develop and evaluate prostate segmentation technique in MRI images.
- b) To develop and perform an algorithm that applies Graph-cut function that can work in MATLAB

The Scopes of Study are:

- a) To test the MRI image with Graph-cut algorithm
- b) To segment and compare the result to Mean-Shift segmentation

CHAPTER 2

LITERATURE REVIEW

2.1 Prostate Cancer

Prostate cancer has become one of the highest cancer-related death cases over the last few years world-wide and especially in western countries such as the United States of America. The number of cases is estimated to be 233,000 men and the number of fatality will be 29,480 [3]. This cancer gave out the symptoms such as difficulty to urinate and dysfunctional of erectile.

This type of cancer is curable and treatable at early stages by doing the clinical practice for early diagnosis. The enhancement of the imaging of the diagnosis is carried out to ensure the result is clear enough to do the analysis. This process is called the segmentation of the prostate gland methodology.

2.2 Clinical Practices

Nowadays, there are numbers of clinical practices carried out to diagnose the existence of carcinoma (cell cancer) in the body of a patient. Throughout these practices, the doctors will plan on the treatment to kill the cell and cure the patient at the same time.

For the prostate cancer, the diagnose practice is usually conducted by using three common methods such as Magnetic Resonance Imaging (MRI) as well as Trans Rectal Ultrasound (TRUS). Computed tomography (CT) imaging is also a common

clinical practice for diagnose of the prostate gland. For this research, the focus is on the MRI scanner.

2.2.1 Magnetic Resonance Imaging (MRI)

Magnetic resonance imaging scanner or dubbed as the MRI scan, is a body scanner that applies techniques of radiology. Magnetism, as well as radio waves, is used by the MRI scanner while scanning a human body. The computer is one of the components that is needed to complete the process to produce body structure images by MRI scanner.

Nowadays, an MRI scan is one of the solutions to detect disease in certain parts of the body. The MRI scan is usually carried out after other testings failed to give out the details to finalize the diagnosis of patient [4].

The MRI scanner is equipped with a large circular magnet that results in the creation of a robust magnetic field. The magnetic field then will be exposed to radiowaves' beams, which then produce a faint signal which is received by the MRI scanner receiver. The data received will be processed and images will be produced by the computer. The advantages of the MRI scan are the images produced are much more detailed. Nevertheless, the poor contrast of images between the soft tissues and some parts of organs make it difficult to read [4].

2.3 Method of Segmentation

There is a lot of methods of segmentation is introduced.

2.3.1 Contour and Shape Based Method

This method utilizes the feature of the contour and shape information of the prostate gland to carry out the segmentation. Afterward, this method is divided into several sub-method; edge-based segmentation, probabilistic filtering and deformable model segmentation.

2.3.1.1 Edge-Based Segmentation

Under this method, a common routine is to use the manipulated gradient filter to extract the edges of an image. Yet, the drawback of this method is the existence of noise gradient filters, whereby the bogus edges is exposed during the process. Furthermore, the detected edges are frequently broken. Despite designated algorithm of computationally expansive edge linking that secure the connection between the edges, the accurate segmentation can be achieved by adding the intensity-based and texture-based information into edge-based algorithms [5].

2.3.1.2 Probabilistic Filtering

Reference to numbers of a journal, type of filters like Kalman filter, as well as particle filters and the probabilistic data association filter (PDAF) is used to segment images.

This method model estimates the probabilistic trajectory of the dynamic object whereby the dynamic model subject is controlling the motion with a particular uncertainty.

This method is also known to be the fastest segmentation algorithm as no optimization is included into the framework [6]. However, the disadvantages of this method are shown to be complicated of the extension and initialization of 3D segmentation.

2.3.2 Deformable Model Segmentation

This method has utilized the theories of mathematical optimization, geometry and physics. Deformable model segmentation method is applying these theories in which every theory carry its very own function; the mathematical optimization carries the works on the model in order to fit in available data, geometry theories focus on the model shape and theories of physics pilot the evolution of shape in space [7]. The common practice of this method is the association between internal

and external energies to the deformable models, whereby the internal energies hold the deformation condition which is the contour smoothness and external energies. These two conditions are used to guide the deformable model to the boundary of an object. The inclusion and combination of the deformable model with the internal and the external energies in a framework are used to segment the structures by edges warping at a minimal deformation of their mean model.

Under this method, there are five methods of the deformable model framework; the first method is active contour model, the second is deformable mesh, the third method is active shape model, the fourth method is level sets and the last one is curve fitting.

2.3.2.1 Active Contour Models (ACM)

ACM or dubbed as the snake. Its works in between the progress deformation by tracing the direction of gradient on them [8] [9].

2.3.2.2 Deformable Mesh

This technique can be fit into a group of method called the parametric deformable mesh in which the kick-off method is to segregate the initial manual segmentation throughout some facets; tetrahedral and triangular [9].

2.3.2.3 Active Shape Model (ASM)

ASM brings a purpose to maintain the structures of anatomical in terms of shape modes arch. This arch is co-related with the component analysis arch which is from the distribution model arch that carry a function to generalize Procrustes analysis with a refer frame [9].

2.3.2.4 Edge Based Level Sets

This group of level framework is a mainstream method in medical imaging segmentation. By which, the development of this method is to study the propagation of the curve in a higher dimension [9].

2.3.2.5 Curve Filling

The curve filling method is using the parametric curves such as splines, as well as parametric curves like ellipses and Bezier to segment prostate. This parametric curve is used due to a minimal difference between the elliptical curve and prostate central gland [9].

2.3.3 Region Based Method

This [9] is a method in which the difference of intensity in the imaging prostate region is exploited, in order to build a segmentation based area algorithm by the developers. Under this method, numbers of sub-method have been introduced.

2.3.3.1 Atlas

The manual segmentation of basic structures is called atlas. It will be logged onto the frequent correlative frame [9]. This atlas also will be the reference to another patient's segmentation images.

2.3.3.2 Graph partition

This method is to produce a graph from the segmentation method and take two data that is important; pixels and edges. First data is a batch of pixels dubbed as nodes. Second is the costs which are derived from edges in a midway of the gradient pixel [9].

2.3.3.3 Region Based Level Sets

This method is called the advance method from the conventional boundary-based level sets in which this method is used as a region-based statistic. The usage of the region-based statistic is for the criteria of energy minimization to propagate the segment the image and level sets [9].

2.3.4 Supervised and Unsupervised Classification Method

This classification method carries an objective to get a space feature partition into labels' sets for different regions. Thus, a technique call clustering and/or classifier are introduced to serve the purpose.

Under this method, there are two methods; a classifier based segmentation and a clustering based segmentation [9].

2.3.4.1 Classifier Based Segmentation

Segmentation based on classifier method is dubbed as the prediction or problem learning. A feature vector and class label (response variable) are tagged with an object in a training set [9]. The usage of this training set is to produce (build) a predictor in which the observation of feature vector could be the basis on the assignation of the class object.

2.3.4.2 Clustering Object Segmentation

Segmentation based on clustering method is aimed to rule out specific formation from the unlabeled set of data by taking some distance measures [9].

2.3.4.3 Mean-Shift Clustering

This method is to join the pixels that have the same density distribution. This method applies the common density which used the x and y are the main variables [20].

2.3.5 Graph Based Segmentation

2.3.5.1 Graph-cut segmentation

This method is cut by the line of image and any pixel where the line becomes nodes. And the image later is partitioned with the 2 nodes on top called the foreground, and below is called the background. Later the nodes on line are connected to the other 2 nodes. And the probability algorithm is assigned to the nodes. The cut image is taking place [23].

2.3.6 Hybrid method

This method is about the combination of segmentation method (prior boundary, region, shape, and feature information of prostate gland) which is the study of noise and produce superior results [9].

CHAPTER 3

METHODOLOGY

3.1 Research Methodology

The research methodologies used in this project are planned to be in the following order.

- a) Literature Review
- b) Selection Of Prostate Segmentation
- c) Basic Block
- d) Method Testing

3.1.1 Literature Review

This research is started by doing the literature review which will help to explain the details and the objectives of the research. The literature review is done by collecting and comparing previous research on the prostate cancer and the technology used in the diagnosis process.

Based on previous research, there are a lot of methods have been introduced in a medicine imaging and deep understanding are needed to select the best method for prostate image enhancement. Thus, numbers of journals, thesis, and articles related to the research are compared and contrasted before being put into the literature review section.

3.1.2 Selection of Prostate Segmentation Method

The second stage of this research is to select the best prostate segmentation method based on the literature review done before doing the test and further experimentation. As highlighted in the literature review, there are numbers of the method related to segmentation but in this project, the scope only focuses on the MRI scanner and graph-cut segmentation. However, in this project, there is three method had been carried out to compare the results;

- a) Edge based segmentation
- b) Graph-cut segmentation
- c) Mean-shift segmentation

3.1.3 Basic Block Diagram of Design

Figure 1 below show a simple block diagram that visualized the flow of process which involves the method of segmentation.

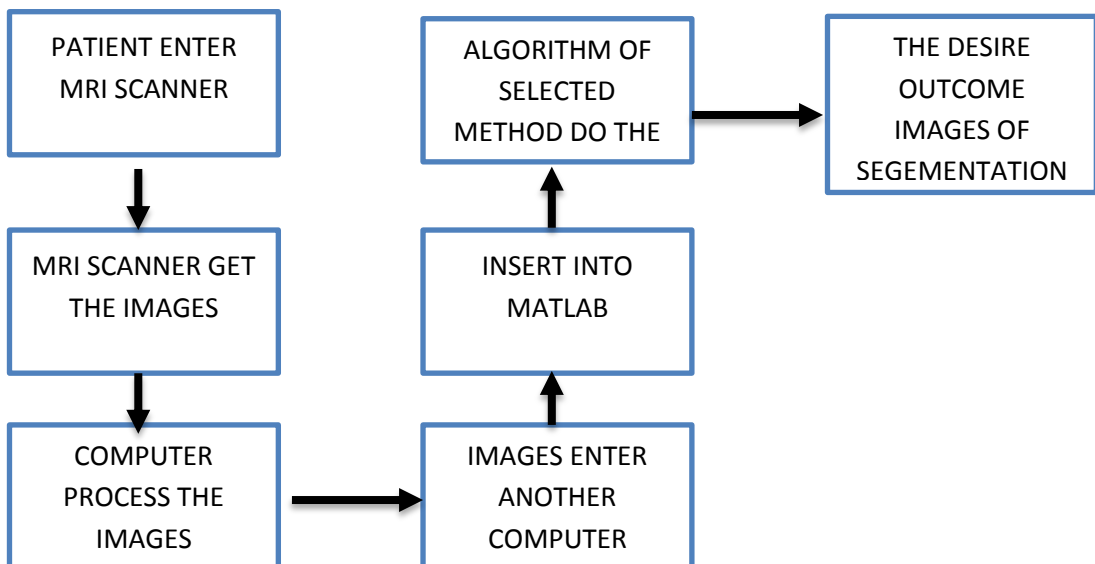


Figure 1: Block Diagram of the Process of Segmentation

The block diagram started with a patient enters the MRI scanner machine. The MRI scanner will conduct its function on the patient's body which later produce

a MRI images on 3 anatomical views; axial (tranverse), sagittal and coronal. For this project, view at axial is taken to enter the algorithm since its more suits to be simulate with the algorithm. The next steps is computer process the images and pass the images to another computer. The image is insert into MATLAB. The algorithm of selected method will be simulating with the images. Finally, the result of simulated images produced and analyses.

3.1.4 Method Testing

After selecting the method, the method algorithm will be tested on the MATLAB platform. It is tested for compatibility and the second testing would be the imaging test, which it is the method which could help in enhancing the image in more detail.

3.2 Project Activities

The basic flow of the project activities is illustrated in Fig.2.

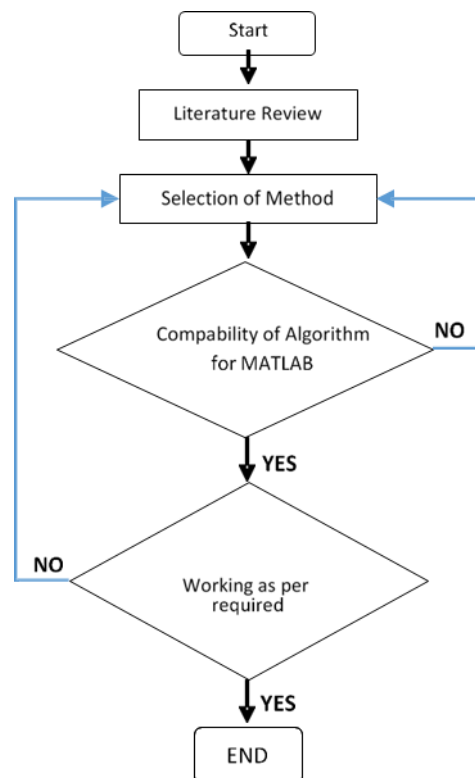


Figure 2: Flow chart of project activities

As shown in Fig.2, the activities start with the literature review whereby the articles, the journal, and the thesis related to this project are needed. This phase helps to build good fundamental on the project itself and also shine out the objectives.

Next, selection of Prostate Segmentation Method is introduced, in which the method related to MRI Scanner practices will be listed out. By then, the method will be selected and tested on the next phase. The testing will be the main examination for the selected method. If the method does not give good results then another method will be selected again from the list as we can see on the Figure 2.

3.3 Key Milestones

Several key milestones must be achieved in order to complete the project.

3.3.1 Literature Review

Literature review needs to be carried out in order to gather the information and get the fundamental basis from all the articles, journals, and the thesis that are related to this project.

3.3.2 Selection of Method

After doing the literature review, the second key milestone is selecting the segmentation method as per objectives of the project. During this selection, two factors need to be the stressed upon; one is that this project is focusing on the MRI project and secondly, the method that is compatible with MATLAB.

3.3.3 Testing the Method on MATLAB

The method testing will be carried in MATLAB. In this phase, the selected method will be tested and prove the theoretical point. If the selected method fails, the research will select another method to be tested. As this programming is much related to the MATLAB, the coding part will be tricky; the coding may not even give out the outcome that the method theoretical stated.

3.3.4 Documentation and Reporting

All data through this project will be documented properly in this phase as no details will be left behind during the compilation.

3.4 Gantt Chart

The Gantt chart for this project can be found in Figure 75 at Appendix A.

3.5 Tools and Equipment Required

Tools and equipment that are needed for this project were MRI images of prostate gland and MATLAB software.

CHAPTER 4:

DISCUSSION AND RESULT

4.1 Discussion

This project needs a deep understanding of the prostate cancer itself. Basic knowledge to the method on diagnosing the prostate cancer itself will be needed to complete this project.

4.1.1 Prostate Gland

The prostate is a small organ that is located above the male reproductive system in between the bladder and urethra. The function of this prostate is producing fluid that consists of proteins and hormones which help keep the sperm alive after ejaculation happens as the sperm search for an egg to inseminate.

The size of this prostate is normally as big as a walnut, about 30-40 grams. Most of the tissue of this organ are built from glandular tissue. Noted that this organ also experiences growth as men age. Research has shown that the size of this organ could be double or triple from the original size. This enlargement of the prostate is not caused by cancer.

The prostate is a small organ that is located above the male reproductive system in between the bladder and urethra. The function of this prostate is producing fluid that consists of proteins and hormones which help keep the sperm alive after ejaculation happens as the sperm search for an egg to inseminate.

The size of this prostate is normally as big as a walnut, about 30-40 grams. Most of the tissue of this organ are built from glandular tissue. Noted that this organ also experiences growth as men age. Research has shown that the size of this organ could be double or triple from the original size. This enlargement of the prostate is not caused by cancer [24].

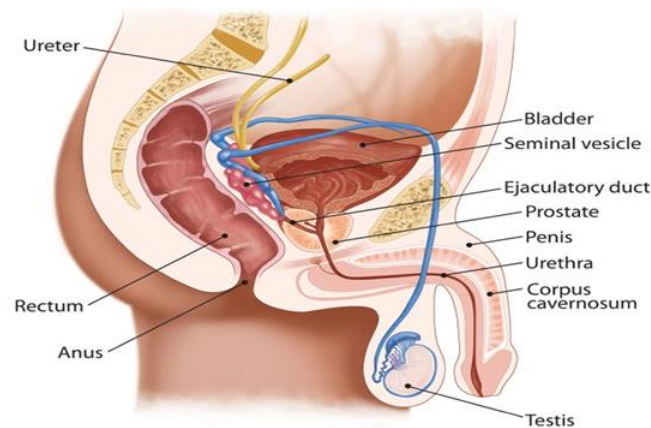


Figure 3: Anatomy of Male Reproduction

4.1.2 Prostate Cancer

Cancer cells that grow inside the prostate gland is called the adenocarcinoma cell. This cell is known as prostate cancer whereby a malignant tumor form from glandular structures in the epithelial tissue. For prostate cases, the cells grow unevenly and unruly at the line of the ducts of the prostate gland. There are cases of the enlargement of the prostate gland called benign prostatic hyperplasia (BPH) but this disease does not belong to cancerous cases. Also, there are occurrences of some other rare cancers but at a low rate.

Despite the increase in numbers of men aged above 50 getting diagnosed with this cancer and a 70% possibility in a man aged 65 and above, researchers try to rule out the factors of one getting this cancer. Attributes that been highlighted are:

- a) Age
- b) Race
- c) Family history

By now, the number of deaths caused by this cancer is decreased by 20% but still the numbers of cases each year still remain at two hundred thousand men estimated to have this cancer in the United States [25].

4.1.3 The Location of Prostate Cancer

We know that the cancerous cells grow at the prostate gland. But throughout MRI images, the experts can assume the area invaded by cancer. The prostate gland is divided into 4 zones; the transition, the anterior, the peripheral and the central. For these 4 zones, only three zones were commonly having growth of the cancerous cell. The percentage of the zone having cancer, 70% is arisen in the peripheral zone, 20% in the transition zone and 10% of the central zone.

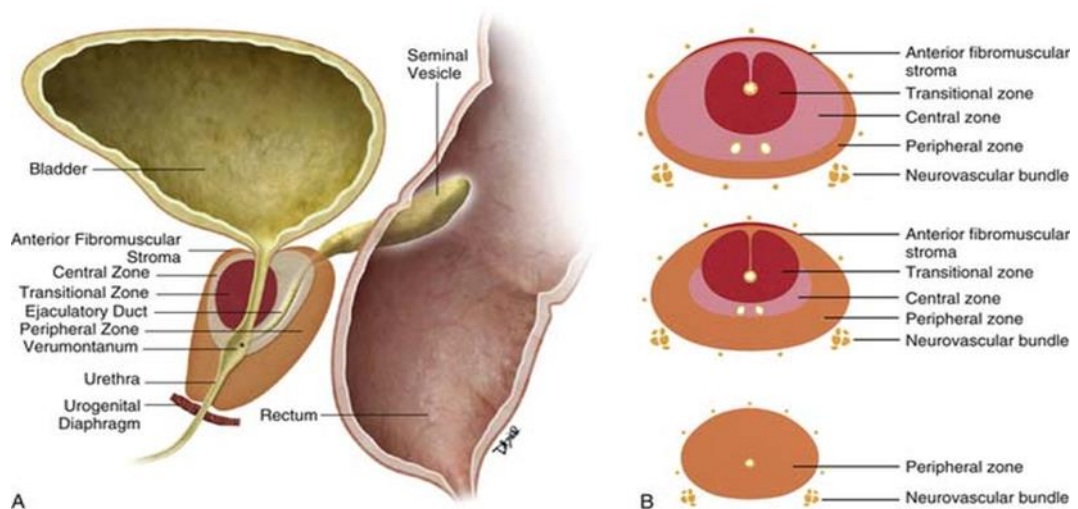


Figure 4: Structure of Prostate

By referring to MRI images, carcinoma cell release low signal intensity. But still, it needs to go through biopsy to get the accurate reading.

4.1.4 The Diagnoses and Staging of the Prostate Cancer

4.1.4.1 Diagnoses of cancer

4.1.4.1.1 Physical examination

This physical examination is a sort of screening process conducted by a doctor to examine the patient before taking another test [10].

- a) Digital rectal exam (DRE)
- b) Prostate-specific antigen (PSA) test

4.1.4.1.2 Clinical practices

After going through the test [11], if there is any abnormality traced, a patient will be advised to take undergo clinical practices such as TRUS, CT scan, and MRI scan.

4.1.4.2 Staging Tumor

For the decision of staging, experts will announce the cancer stage by seeing the result of the test and biopsy carried out. Prostate cancer tumor will be classified into this class:

Table 1: Type of Tumor.

Type OF Tumour	Condition
T	Primary tumour
T1	Clinically inapparent tumour not palpable or visible by imaging
T2	Tumour confined within the prostate
T3	Tumour extending through the prostatic capsule; no invasion into the prostatic apex or into, but not beyond, the prostatic capsule
T4	Tumour fixed or invading adjacent structures other than

	seminal vesicles (e.g. Bladder neck, external sphincter, rectum, levator muscles, pelvic wall)
--	--

This classification is the simple classification as there is an alphabet class for each tumor classification. Thus, the cancer stage will be decided on the type of tumor that patient has.

Table 2: Staging of Cancer.

Stage I	Stage II	Stage III	Stage IV
This stage signifies very early cancer that's confined to a small area of the prostate. When viewed under a microscope, the cancer cells aren't considered aggressive.	Cancer at this stage may still be small but may be considered aggressive when cancer cells are viewed under the microscope. Or cancer that is stage II may be larger and may have grown to involve both sides of the prostate gland.	The cancer has spread beyond the prostate to the seminal vesicles or other nearby tissues.	Cancer has grown to invade nearby organs, such as the bladder, or spread to lymph nodes, bones, lungs or other organs.

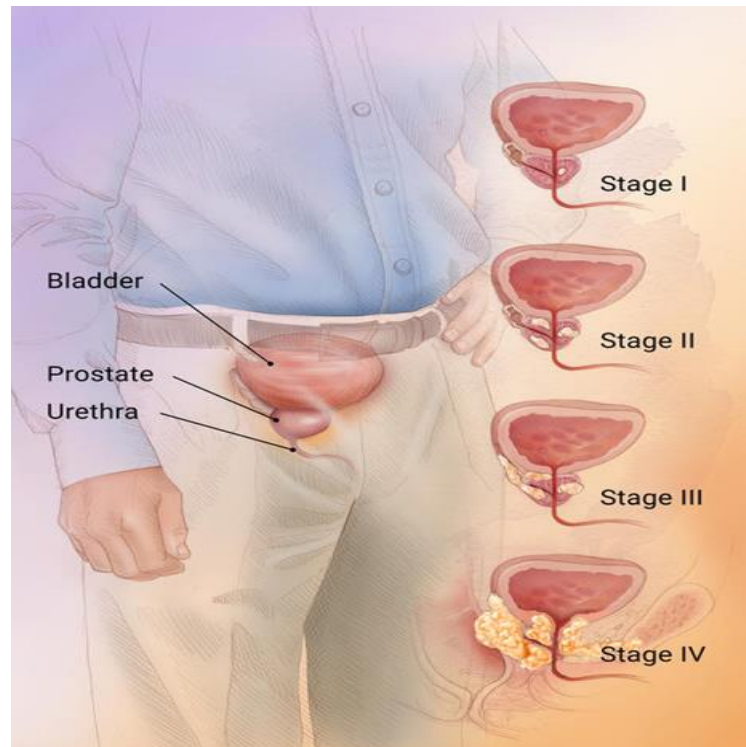


Figure 5: Stage of prostate cancer

4.2 Result

This subtopic is segregated into 4 parts.

Currently, a lot of clinical practices have been introduced to the world regarding the segmentation of images. Most of the patients' diagnoses are using the common clinical practice such as Magnetic Resonance Imaging (MRI) as well as Trans Rectal Ultrasound (TRUS). Computed tomography (CT) imaging is also a common clinical practice for diagnoses of the prostate gland. For this research, the spotlight will be on the MRI scanner only.

As per discussed in Chapter 2, there are numerous methods of enhancing images of all clinical practices for diagnosing the prostate cancer. From the thirteen (15) methods, only 7 of them is applicable to MRI images. The types of methods related to the MRI are:

- a) Edge based segmentation
- b) Deformable model based segmentation

- c) Active shape model
- d) Atlas
- e) Hybrid segmentation
- f) Mean-Shift Segmentation
- g) Graph-cut segmentation

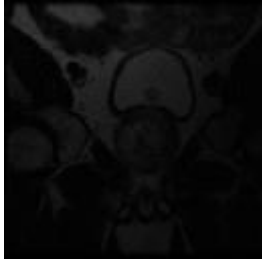
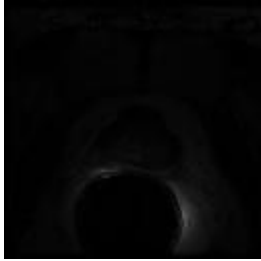

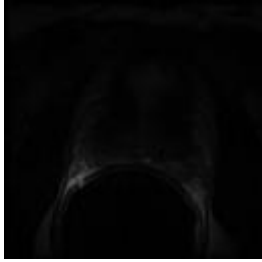

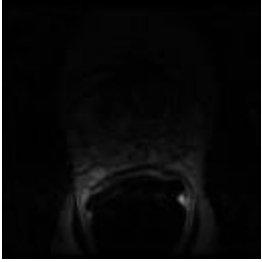
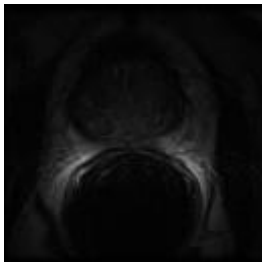
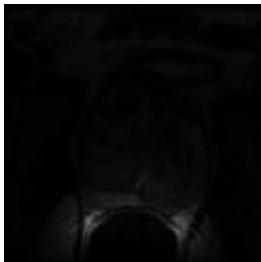
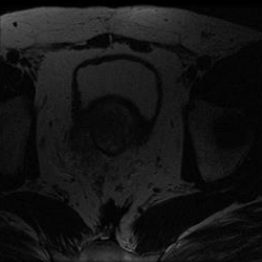
As mention before, there is three methods only experimented for this experiment which is Edge based segmentation, Graph-cut segmentation and Mean-shift segmentation.

Over several months, this project saw some algorithms used to reach the objectives of this project. As numbers of the methods are fixed with the MRI image, the outcome of these methods varied.

This part of study needs to be manipulated so that the results can capture the intensity of the images. MRI images are known to be gray-scale and thus, the intensity would be either to black or to white.

As for Section 2.2 and 2.3, 9 images are selected to go through the algorithm and the result recorded. Section 4.1 shows the result recorded from the k mean algorithm. Section 2.2 is a section where all results due to mean shift is shown.

Table 3: Selected MRI Images.

 <p>Figure 6: Image (a)</p>	 <p>Figure 7: Image (b)</p>	 <p>Figure 8: Image (c)</p>
 <p>Figure 9: Image (d)</p>	 <p>Figure 10: Image (e)</p>	 <p>Figure 11: Image (f)</p>
 <p>Figure 12: Image (g)</p>	 <p>Figure 13: Image (h)</p>	 <p>Figure 14: Image (i)</p>

4.2.1 Segmentation Using Edge Based

Currently, this section focuses on the edge based segmentation which extracts the region of interest from the original image by submitting the selected MRI image of a patient into coding. For this phase, the images will go through Prewitt filter to get the perfect edge.

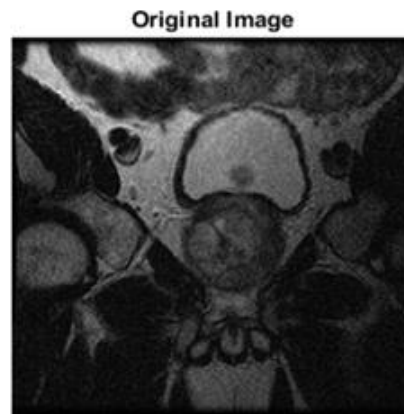

Figure 15: Original MRI image

As shown above, that is the original image of the patient suspected of having prostate cancer.




Figure 16: Original Image Goes Through Prewitt Filter

This filter helps to form a very nice circle on the R.O.I but there are other unwanted edges.




Figure 17: Filtered Image with Clean Edge Of The R.O.I

From the result, the next step will be to eliminate the unwanted edge from the other organ. This will be included in the future plan of the project. Also, the next algorithm to apply to this project will be the Mean Shift Segmentation.

4.2.2 Segmentation Using Mean Shift

Five selected MRI images of prostate (a, b, c, d, e, f, g, h and i) with fixed dimension of 256 x 256 pixels on the figure 5, 6, 7, 8, 9, 10, 11, 12 and 13. All of these nine images are taken from different patients so the size of the prostate gland is varied and some of them are already at bulging phase which means the cancer has already spread out to the organ. These MRI images are fully built in gray scale format. Thus, the segmentation will utilize the pixel from 0 to 1 of the image.

For this algorithm, two variables will experience a variation of numbers. First variable is called x which is the size of the processing window. Next variable is derived as y . It represents a range of kernel size (one point to another point).

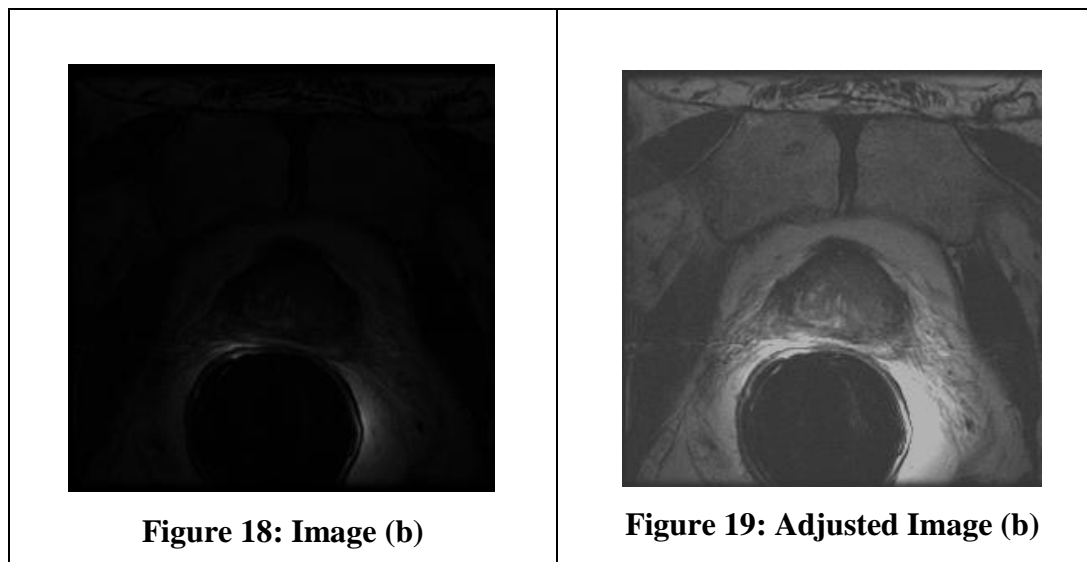
Furthermore, this method will divide the picture pixels into numbers of groups which is represented by the colors. The groups will be divided depending on the number of clusters (k). The selected image is simulated by the algorithm. The algorithm will crop the size of the image into a smaller size which only focuses on the R.O.I.

The image is put into the fixed algorithm so that the result can be compared. The image is also cut into a certain size which then focuses on the ROI. Some images have the big ROI images and some have the small R.O.I. Time for each image to be simulated prompt differing results. The simulation takes 3 minutes to 45 minutes to be completed.

In this subtopic, there are two parts of procedure needed to be done. First, need to find the best pairing of x-y variables that could give a better result on showing or segregate the R.O.I from the images. On the second procedure, after finding the best pairing of the x-y variables, all the images will be simulated into the algorithm with same x-y variables and the results compared.

The first image, labeled Figure (b), the images will enter the contrast algorithm that would revise the contrast of an image. Thus, the distinguishing of R.O.I from the background became clearer.

Table 4: Result of Adjusted Brightness.



The new image of Figure (b) then enters into the algorithm and simulated with fixed window processing size.

Table 5: Image (b) with different y-axis

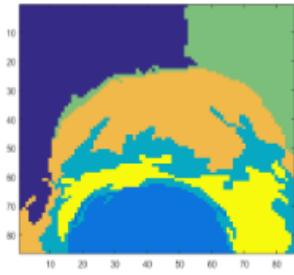


Figure 20: X=40, y=1

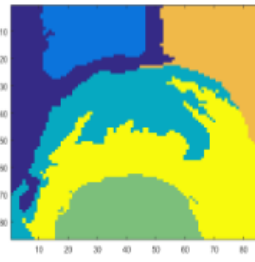


Figure 21: X=40, y=2

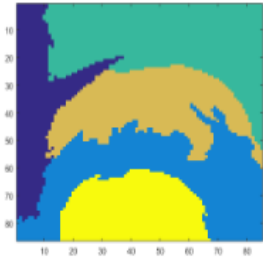


Figure 22: X=40, y=3

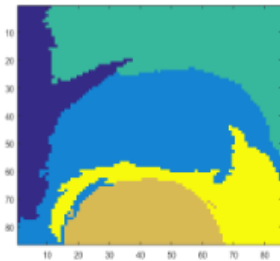


Figure 23: X=40, y=4

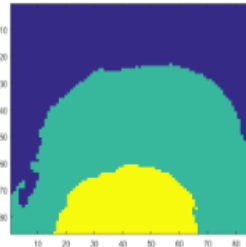


Figure 24: X=40, y=5

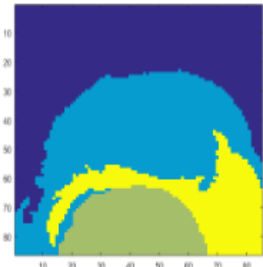


Figure 25: X=40, y=6

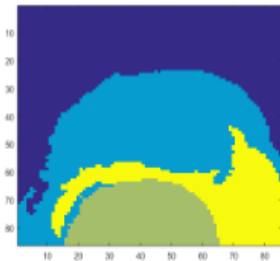


Figure 26: X=40, y=7

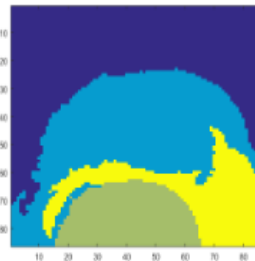


Figure 27: X=40, y=8

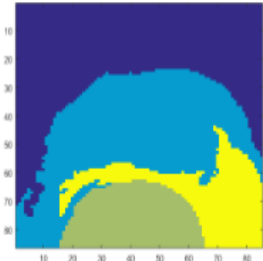


Figure 28: X=40, y=9

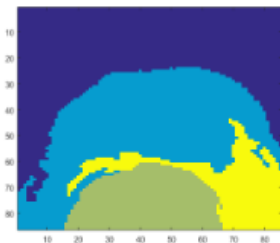
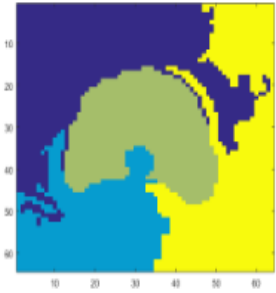


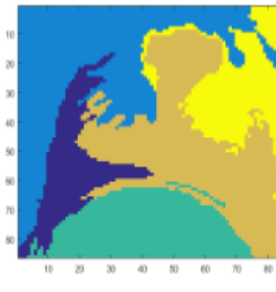

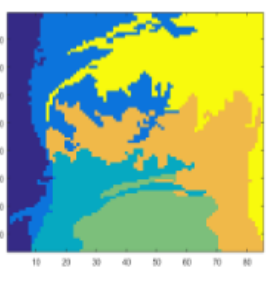
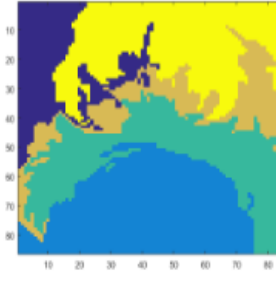
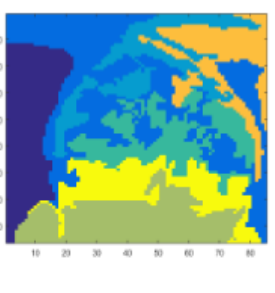



Figure 29: X=40, y=10

As the result shows, at every increment of y value, the cluster groups in the image decrease and the time taken to complete one image is getting lower as they increase. The results also show that the region of interest (R.O.I) gradually disappears from the images as y increases. The best result is from the pairing of $x=40$ and $y=1$ as the details of mean shift of the region of interest (R.O.I) is perfectly shown.

Hence, after comparing the result from the resulting images, all other images is entered into MATLAB and simulated. Below is the result of simulation:

Table 6: Result of Mean Shift on All Images

 <p>Figure 30: Mean Shift Figure (a)</p>	 <p>Figure 31: Mean Shift Figure (b)</p>	 <p>Figure 32: Mean Shift Figure (c)</p>
 <p>Figure 33: Mean Shift Figure (d)</p>	 <p>Figure 34: Mean Shift Figure (e)</p>	 <p>Figure 35: Mean Shift Figure (f)</p>
 <p>Figure 36: Mean Shift Figure (g)</p>	 <p>Figure 37: Mean Shift Figure (h)</p>	 <p>Figure 38: Mean Shift Figure (i)</p>

From the result, R.O.I of certain images is smoothen out even though variable γ was set up very low. For example, in Figure (d) and Figure (j).

Table 7: Result Image (d)

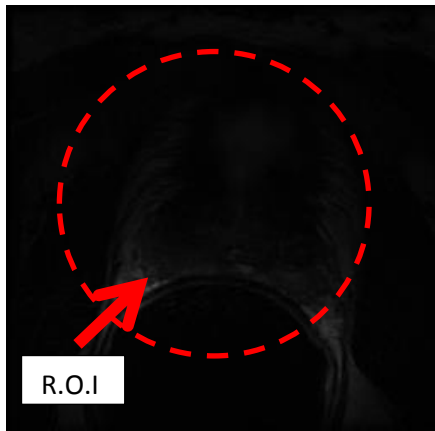


Figure 39: Image (d)

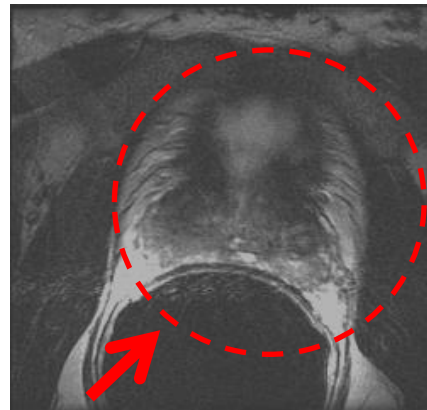


Figure 40: Figure(d) after adjusted contrast

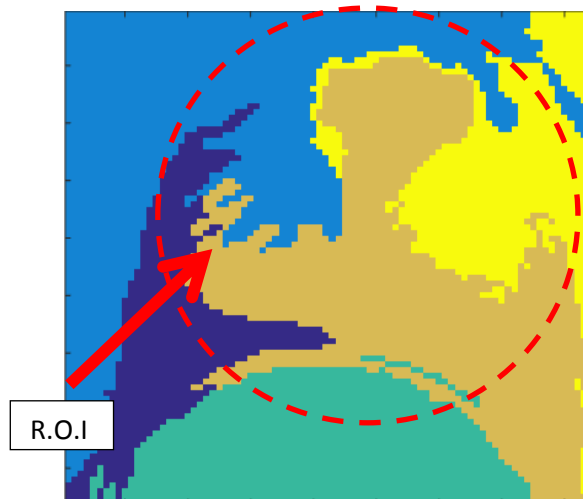


Figure 41: Mean Shift Figure (d)

Referring to the table above, at the resulting image, only the middle part of the prostate gland can be seen. The other part of the gland was smoothen out by the algorithm.

Opposite result from Figure (d) and Figure (j), the result for another image was better and the most successful result is shown by Figure(a).

Table 8: Result of Image (a)

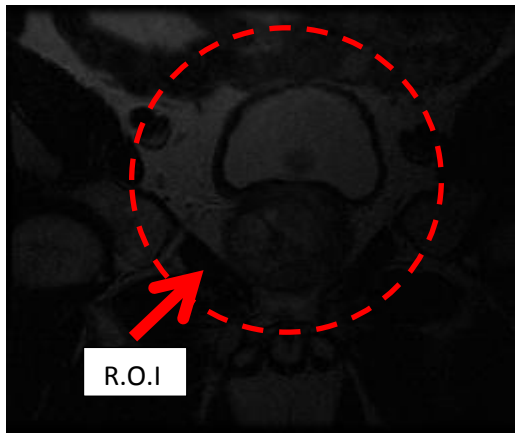


Figure 42: Image (a)

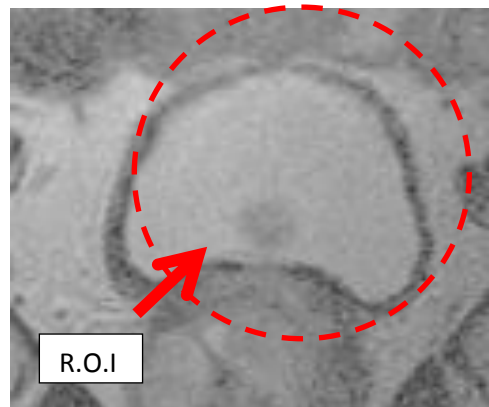


Figure 43: Figure (a) after adjusted contrast

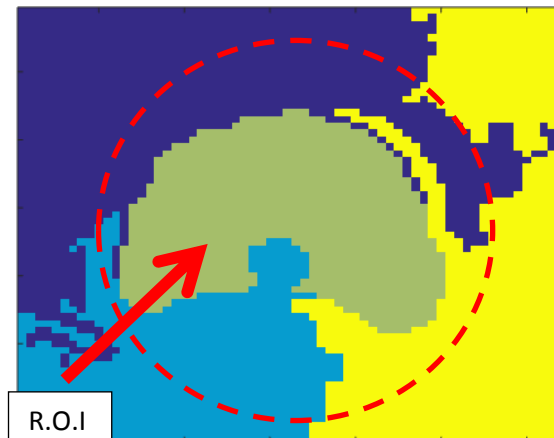
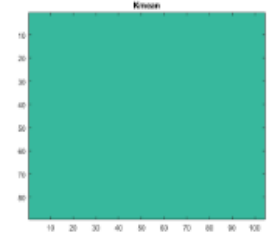
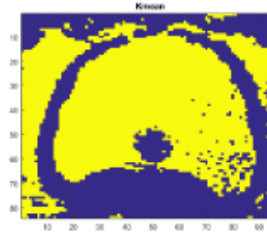
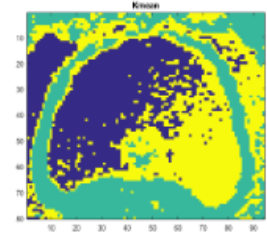
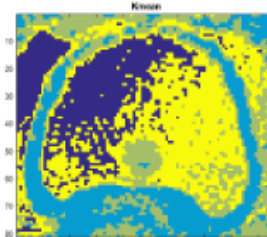
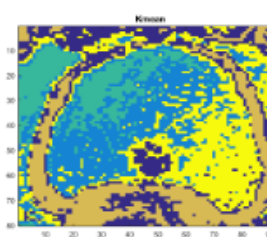
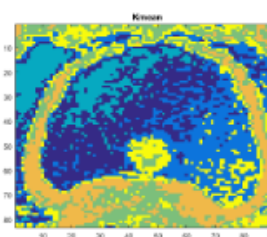
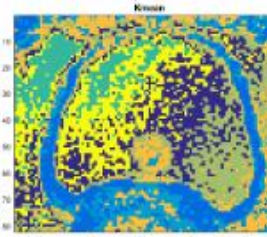
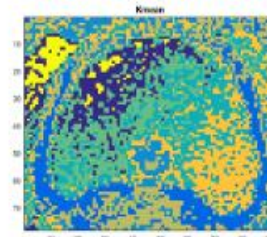


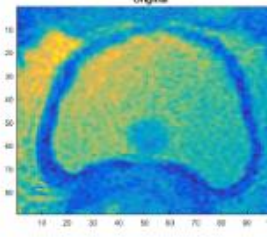


Figure 44: Mean Shift Figure (a)

4.2.3 Segmentation Using Graph-cut

For this method, the main variable is focusing more on the number of clusters (k). Following the same procedure in Section 4.1, one of the images will be tested with a number of the clusters from 1 to 10 as the objective is to find the number of the clusters that could give the best result.

Table 9: Image (a) with vary number of cluster (k)

 <p>Figure 45: Image (a) K=1</p>	 <p>Figure 46: Image (a) K=2</p>	 <p>Figure 47: Image (a) K=3</p>
 <p>Figure 48: Image (a) K=4</p>	 <p>Figure 49: Image (a) K=5</p>	 <p>Figure 50: Image (a) K=6</p>
 <p>Figure 51: Image (a) K=7</p>	 <p>Figure 52: Image (a) K=8</p>	 <p>Figure 53: Image (a) K=9</p>
 <p>Figure 54: Image (a) K=10</p>	 <p>Figure 55: Image (a) pre K-mean</p>	

From the table above, as the k gradually increase, the resulting image gets messier. Looking at the figure in which k equals 2 to 4 is considered as a success as the number of clusters (color) are not messed up and show the R.O.I clearly.

Compared to k equal to 10, it's full of colors that disturb the R.O.I from visibility clearly. So, from the result, all other images will go through the algorithm with a number of clusters equal to 4.

Table 10: All images with k-mean of $k=4$

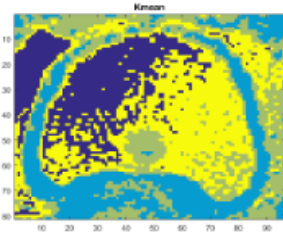
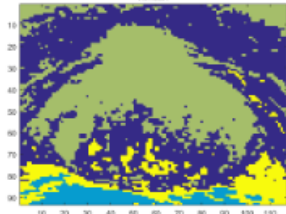
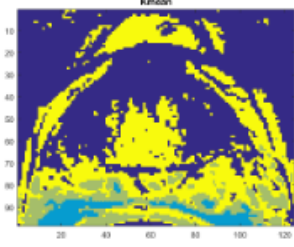
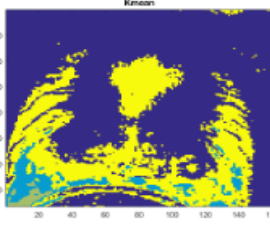
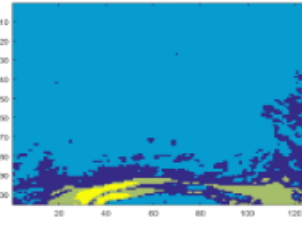
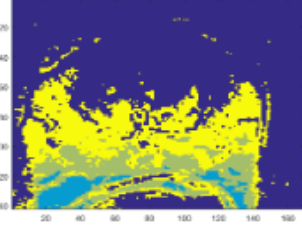
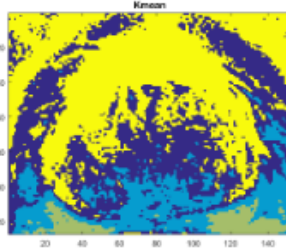
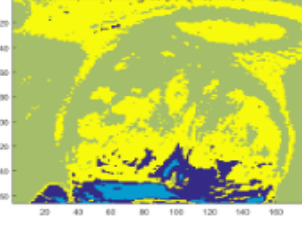
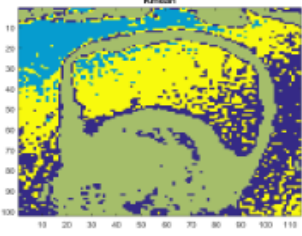
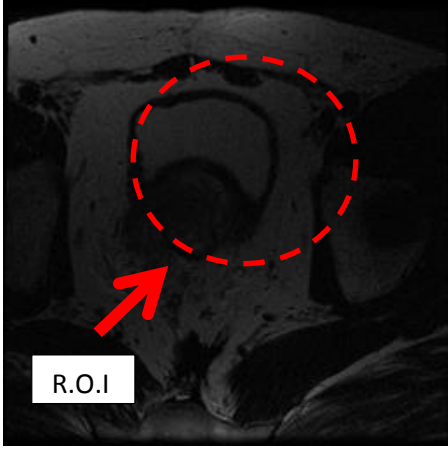
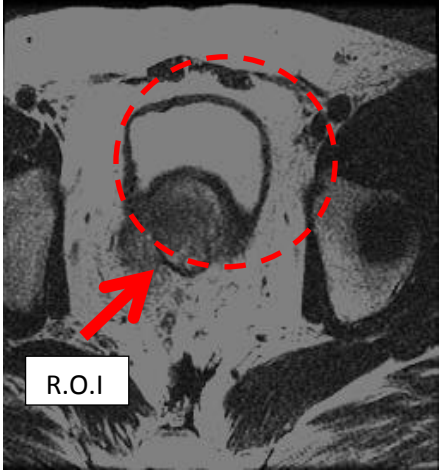
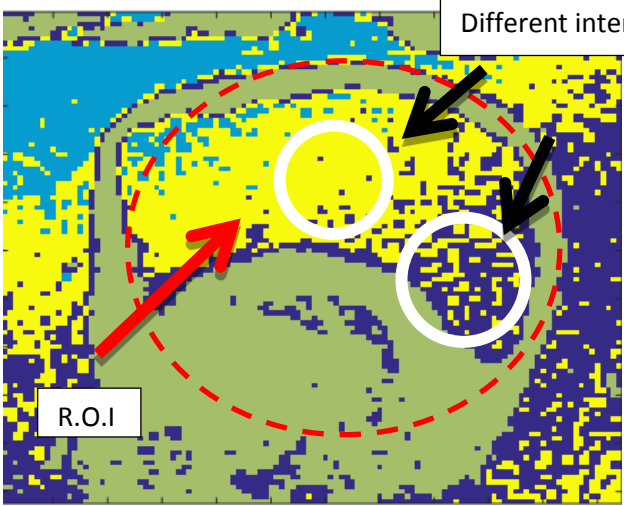
 <p>Figure 56: $k=4$ Figure (a)</p>	 <p>Figure 57: $k=4$ Figure (b)</p>	 <p>Figure 58: $k=4$ Figure (c)</p>
 <p>Figure 59: $k=4$ Figure (d)</p>	 <p>Figure 60: $k=4$ Figure (e)</p>	 <p>Figure 61: $k=4$ Figure (f)</p>
 <p>Figure 62: $k=4$ Figure (g)</p>	 <p>Figure 63: $k=4$ Figure (h)</p>	 <p>Figure 64: $k=4$ Figure (i)</p>


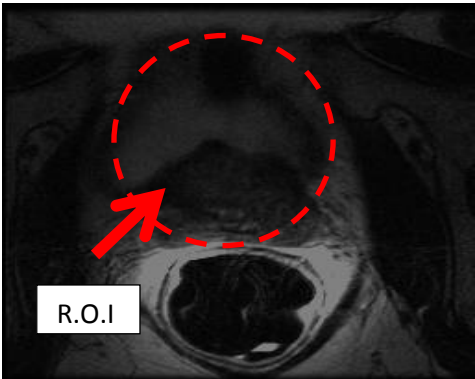
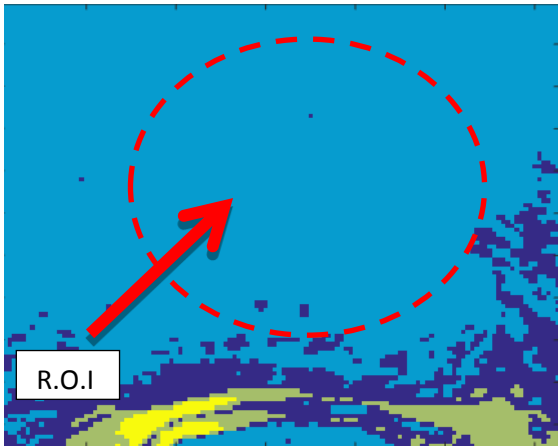
Figure (e), R.O.I is covered with the clusters. For a successful result such as Figure (i), the R.O.I is visible to the examiner to look at it.

Table 11: Result of image (i)

 <p data-bbox="368 831 469 875">R.O.I</p> <p data-bbox="443 936 678 965">Figure 65: Image (i)</p>	 <p data-bbox="938 831 1038 875">R.O.I</p> <p data-bbox="874 949 1380 978">Figure 66: Figure (i) after adjusted contrast</p>
 <p data-bbox="1011 1077 1273 1122">Different intensity</p> <p data-bbox="596 1469 697 1514">R.O.I</p> <p data-bbox="724 1599 1011 1628">Figure 67: k=4 Figure (i)</p>	

Above result of the Figure (i) show a clear picture of the prostate gland and also, the clusters managed to show up the difference of intensity of the image which is important in diagnosis cancer. Cancer usually shows a differing intensity of dark compared to the cells around them. For the opposite result, refer Figure (e) below.

Table 12: result of image (e)

 <p>Figure 68: Image (e)</p>	 <p>Figure 69: Figure(e) after adjusted contrast</p>
 <p>Figure 70: k=4 Figure (e)</p>	

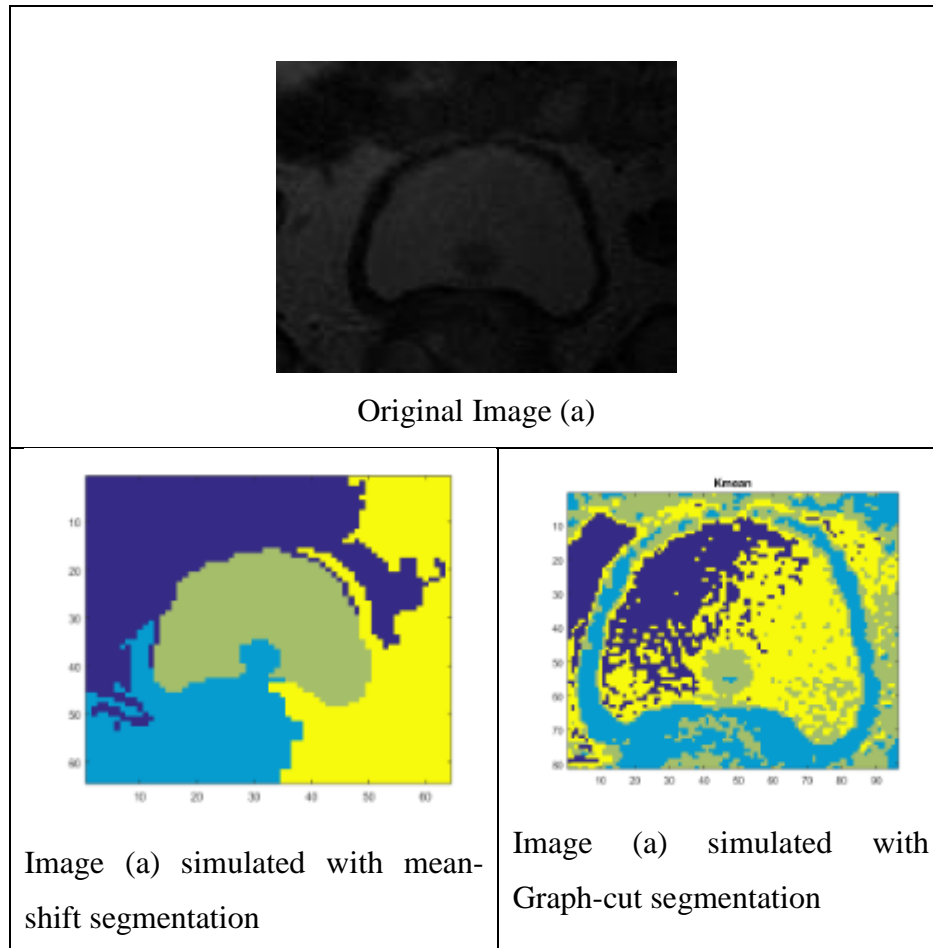
From above table, the result of the Figure (e) is not giving out the expected result as the cluster wiped down the R.O.I area.

4.2.4 The comparison between Graph-cut segmentation and Mean Shift segmentation

At early stage, edge based method is considered as not fail and not suits for this project objectives. The comparison is carried out by comparing method graph-cut and mean shift. The comparison is aims to compare the effectiveness and accuracy of algorithm catch region of interest.

The comparison is comparing between the best result from both methods,

Table 13: The Comparison between Mean-Shift Segmentation and Graph-Cut Segmentation.



As per shown, image (a) is simulated into two method and giving out very different result. on left side, mean shift segmentation result shows R.O.I shape and exclude all surroundings, on right side, the graph-cut images managed to differentiate between R.O.I and surrounding.

In diagnosing of MRI images, the surrounding of prostate gland is important in diagnosing carcinoma cell. the probability that cancer cells burst at the surrounding. Its showing that the Graph-cut segmentation abide the rules of diagnoses of MRI.

Refer back to result of graph-cut segmentation, the image showing different colour intensity on R.O.I. under the study of MRI, cancer cells that exists on the organ showing lower intensity compare to the cell on the organ itself. So, there is probablity that the cancer cells exist on that darker region of R.O.I.

Hence, from the comparison, the graph-cut managed to abide and help to diagnosed the image compare to mean-shift segmentation. On next section, the test on the accuracy of segmentation of Graph-cut.

4.2.5 The Accuracy of Segmentation of Graph-cut

Under this subtopic, the experiment continued by evaluating the accuracy of segmentation on segregation between pixels. The experiment is conducted by selecting 5 parts of MRI image of a patient which is homogenous in color. Then the images are combined into one single row and simulated into the Graph-cut algorithm.

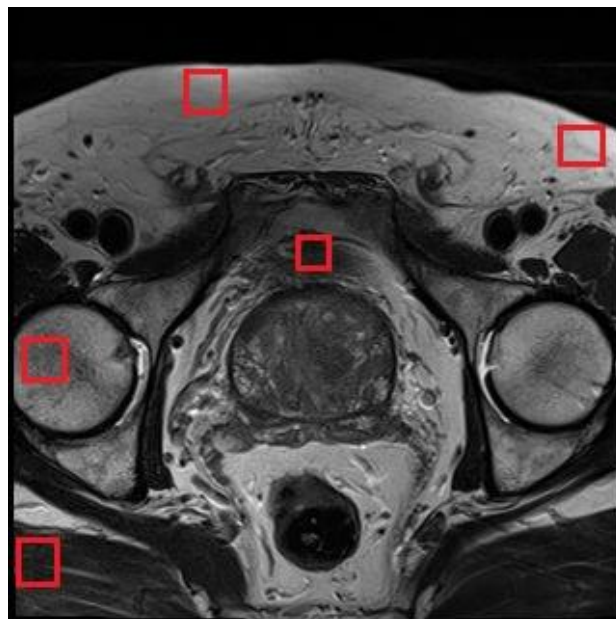


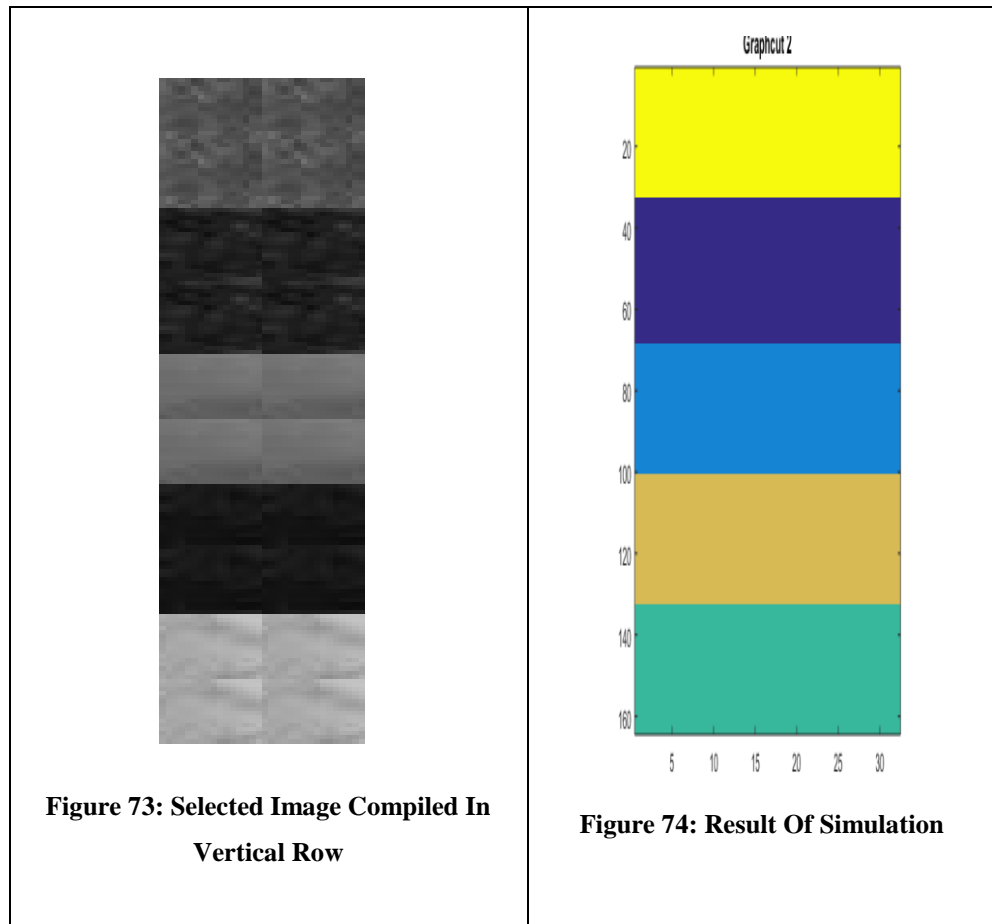
Figure 71: MRI images with selected parts.



Figure 72: selected image compiled in vertical row

Figure 72 later simulated into algorithm, which produced result as below.

Table 14: Result of Simulated Images



The result shows that the Graph-cut manage to distinguish between 5 regions with different colors without mixing them together.

CHAPTER 5:

CONCLUSION AND RECOMMENDATION

5.1 Conclusion

Due to the soft tissues which surround the prostate gland, the segmentation of the subject was not an easy task. The study and testing is carried out by using the Graph-cut on the selected images. Later, the result of the Graph-cut is compared with mean-shift segmentation result whereby the results are showing differently.

To summarize, this project is not concluded yet as there is a lot of experiment and testing that can be carried on in future.

5.2 Recommendation and Future Work

As shown above, the result shows a positive side of improvement. Unfortunately, this result cannot be the conclusion towards this project. As per discussion with supervisors, this project needs to be confirmed with other method testing such as using distribution factors etc. (which is a master level project). One of the methods that can be use is function of imhist (MATLAB function) to get the distribution factor of every selected homogenous part and repeating the trend to other images will see the effectiveness of segmentation.

REFERENCES

- [1] Prostate Cancer Statistics - Key Facts, info.cancerresearchuk.org/cancerstats/types/prostate, accessed on [1st April, 2011], 2011
- [2] What are the key statistics about prostate cancer? (n.d.). Retrieved October 28, 2015.
- [3] R. Siegel, J. Ma, Z. Zou, and A. Jemal, "Cancer statistics, 2014," *CA Cancer J. Clin.*, vol. 64, no. 1, pp. 9-29, Jan.2014.
- [4] MRI: Get the Facts and Risks of Magnetic Resonance Imaging. (n.d.). Retrieved October 27, 2015.
- [5] Zaim, A., "An edge-based approach for segmentation of prostate ultrasound images using phase symmetry," in *Communications, Control and Signal Processing, 2008. ISCCSP 2008. 3rd International Symposium on*, vol., no., pp.10-13, 12-14 March 2008
- [6] Weiler, D.; Willert, V.; Eggert, J.; Korner, E., "A Probabilistic Method for Motion Pattern Segmentation," in *Neural Networks, 2007. IJCNN 2007. International Joint Conference on*, vol., no., pp.1645-1650, 12-17 Aug. 2007
- [7] Subasic, M.; Loncaric, S.; Sorantin, E., "Region-based deformable model for aortic wall segmentation," in *Image and Signal Processing and Analysis, 2003. ISPA 2003. Proceedings of the 3rd International Symposium on*, vol.2, no., pp.731-735 Vol.2, 2003.
- [8] Da Yuan, "An Efficient and Reliable Segmentation Method Based on Active Contour Model," in *Intelligent Robots and Systems, 2006 IEEE/RSJ International Conference on*, vol., no., pp.5816-5818, 2006.

- [9] Zhong Liu; Chan, S.C.; Chong Wang; Shuai Zhang, "Multi-view articulated human body tracking with textured deformable mesh model," in Circuits and Systems (ISCAS), 2015 IEEE International Symposium on , vol., no., pp.1038-1041, 2015.
- [10] Takahashi, H.; Komatsu, M.; Hyoungseop Kim; Joo Kooi Tan; Ishikawa, S.; Yamamoto, A., "Segmentation method for cardiac region in CT images based on active shape model," in Control Automation and Systems (ICCAS), 2010 International Conference on , vol., no., pp.2074-2077, 2010.
- [11] Xinbo Gao; Bin Wang; Dacheng Tao; Xuelong Li, "A Relay Level Set Method for Automatic Image Segmentation," in Systems, Man, and Cybernetics, Part B: Cybernetics, IEEE Transactions on , vol.41, no.2, pp.518-525, April 2011
- [12] Medina, R.; Bravo, A.; Windyga, P.; Toro, J.; Yan, P.; Onik, G., "A 2-D Active Appearance Model For Prostate Segmentation in Ultrasound Images," in Engineering in Medicine and Biology Society, 2005. IEEE-EMBS 2005. 27th Annual International Conference of the, vol., no., pp.3363-3366, 17-18 Jan. 2006
- [13] Gang Chen; Tai Hu; Xiaoyong Guo; Xin Meng, "A fast region-based image segmentation based on least square method," in Systems, Man and Cybernetics, 2009. SMC 2009. IEEE International Conference on, vol., no., pp.972-977, 11-14 Oct. 2009
- [14] Ghose, S.; Mitra, J.; Oliver, A.; Marti, R.; Llado, X.; Freixenet, J.; Vilanova, J.C.; Sidibe, D.; Meriaudeau, F., "A coupled schema of probabilistic atlas and statistical shape and appearance model for 3D prostate segmentation in MR images," in Image Processing (ICIP), 2012 19th IEEE International Conference on , vol., no., pp.541-544, Sept. 30 2012-Oct. 3 2012
- [15] Jianzhong Wang; Di Liu; Lili Dou; Baoxue Zhang; Jun Kong; Yinghua Lu, "Graph theory based algorithm for magnetic resonance brain images

- segmentation," in BioInformatics and BioEngineering, 2008. BIBE 2008. 8th IEEE International Conference on, vol., no., pp.1-5, 8-10 Oct. 2008
- [16] Dubrovina-Karni, A.; Rosman, G.; Kimmel, R., "Multi-Region Active Contours with a Single Level Set Function," in Pattern Analysis and Machine Intelligence, IEEE Transactions on , vol.37, no.8, pp.1585-1601, Aug. 1 2015
- [17] Karoui, I.; Fablet, R.; Boucher, J.-M.; Augustin, J., "Variational Region-Based Segmentation Using Multiple Texture Statistics," in Image Processing, IEEE Transactions on , vol.19, no.12, pp.3146-3156, Dec. 2010
- [18] Rohlfing, T.; Russakoff, D.B.; Maurer, C.R., Jr., "Performance-based classifier combination in atlas-based image segmentation using expectation-maximization parameter estimation," in Medical Imaging, IEEE Transactions on , vol.23, no.8, pp.983-994, Aug. 2004
- [19] Yixin Yan; Yongbin Shen; Shengming Li, "Unsupervised Color-Texture Image Segmentation Based on A New Clustering Method," in New Trends in Information and Service Science, 2009. NISS '09. International Conference on , vol., no., pp.784-787, June 30 2009-July 2 2009
- [20] Y. m. Zhou, S. y. Jiang and M. l. Yin, "A Region-Based Image Segmentation Method with Mean-Shift Clustering Algorithm," Fuzzy Systems and Knowledge Discovery, 2008. FSKD '08. Fifth International Conference on, Shandong, 2008, pp. 366-370. doi: 10.1109/FSKD.2008.363
- [21] Awad, M.; Chehdi, K.; Nasri, A., "Enhancement of the segmentation process of multi-component images using fusion with Genetic Algorithm," in Systems, Signals and Devices, 2008. IEEE SSD 2008. 5th International Multi-Conference on , vol., no., pp.1-6, 20-22 July 2008
- [22] Soumya Ghose, Arnau Oliver, Robert Martí, Xavier Lladó, Joan C. Vilanova, Jordi Freixenet, Jhimli Mitra, Désiré Sidibé, Fabrice Meriaudeau, A survey of prostate segmentation methodologies in ultrasound, magnetic resonance and

computed tomography images, *Computer Methods and Programs in Biomedicine*, Volume 108, Issue 1, October 2012, Pages 262-287, ISSN 0169-2607, <http://dx.doi.org/10.1016/j.cmpb.2012.04.006>.

- [23] F. Yi and I. Moon, "Image segmentation: A survey of graph-cut methods," *Systems and Informatics (ICSAI), 2012 International Conference on*, Yantai, 2012, pp. 1936-1941. doi: 10.1109/ICSAI.2012.6223428

- [24] <http://www.macmillan.org.uk/information-and-support/prostate-cancer/early-prostate-cancer/understanding-cancer/the-prostate-gland.html>

- [25] Prostate Cancer. (n.d.). Retrieved April 18, 2016, from <http://www.cancer.org/cancer/prostatecancer/>

APPENDIX

No.	Project Activities														
		1	2	3	4	5	6	7	8	9	10	11	12	13	14
1	Deciding Project Title														
2	Literature Review														
3	Extended Proposal Preparation														
4	Extended Proposal Submission														
5	Selection of Method														
6	Test the method selected on MATLAB														
7	Proposal Defense Preparation														
8	Interim Report Preparation														
9	Draft Interim Report Submission														
10	Final Interim Report Submission														
FYP II															
11	Simulate the images with algorithm														
12	Pre-SEDEX														
13	Submission of Draft report														
14	Submission of technical report														
15	Submission of final report														
16	Viva														

Figure 75: Gantt chart